PRACTICE AID

HRCT in SSc-ILD[1,2]

PeerView INSTITUTE FOR MEDICAL EDUCATION

MLI Medical Learning Institute, Inc.



Ground-glass opacities (red arrow) and traction bronchiectasis suggestive of NSIP in SSc-ILD

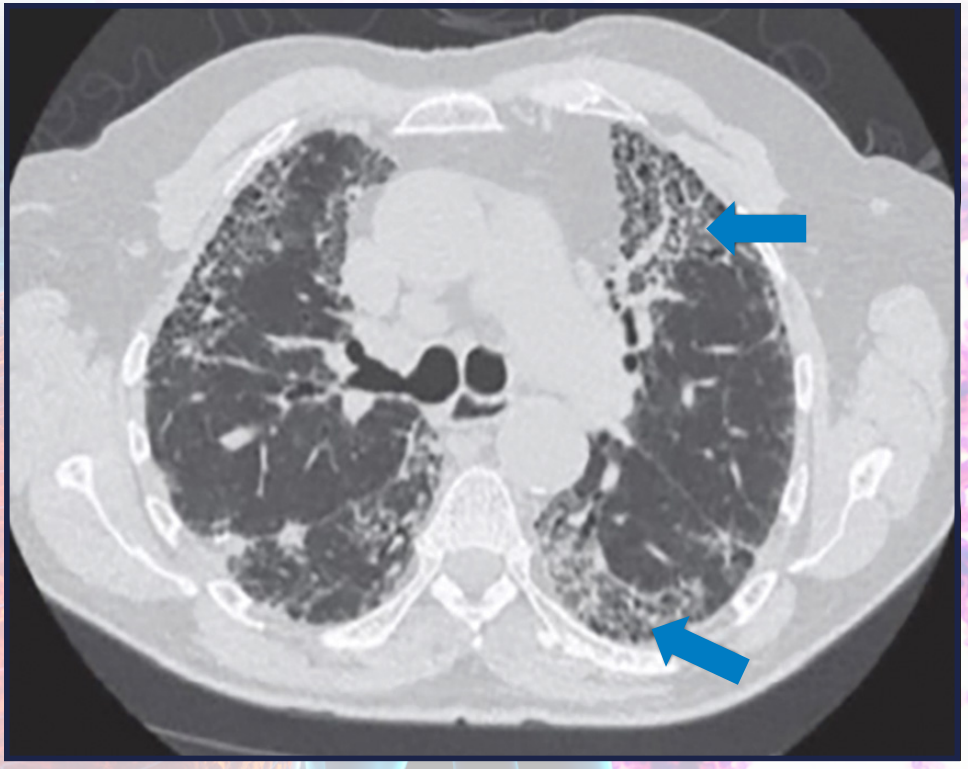

Honeycombing (blue arrows) with ground-glass opacities suggestive of UIP in SSc-ILD

HRCT: high-resolution computed tomography; NSIP: nonspecific interstitial pneumonia; SSc-ILD: systemic sclerosis–associated interstitial lung disease; UIP: usual interstitial pneumonia.

1. Chung JH. *Am J Radiol*. 2018;210. 2. Castelino FV et al. *Arthritis Res Ther*. 2010;12:213.

Access the activity, "How I Think, How I Treat – Contemporary Insights on Diagnosing and Managing SSc-ILD in an Evolving Treatment Landscape," at **PeerView.com/RUB40**